

## First record of microfilariae in *Antilophia galeata* (Aves: Pipridae)

Paulo Vitor Alves Ribeiro<sup>a\*</sup>, Márcia Cristina Cury<sup>b</sup>, Celine de Melo<sup>a</sup>

<sup>a</sup> Laboratório de Ornitologia e Bioacústica, Universidade Federal de Uberlândia, Minas Gerais, 38400-902, Brasil.  
\*paulovitorbio@gmail.com

<sup>b</sup> Laboratório de Sorologia e Biologia Molecular de Parasitos, Universidade Federal de Uberlândia, Minas Gerais, 38400-902, Brasil.

Received: December 1, 2019 / Accepted: February 18, 2020 / Published online: May 25, 2020

### Abstract

Filarid nematodes are transmitted by arthropod vectors. In the vertebrate host, they inhabit the cardiovascular, pulmonary, and lymphatic system. Although most bird infections are not considered pathogenic, there may be an impact on fitness. Blood smears were performed to verify the intensity of the infection and to morphometrically analyse and describe the microfilariae found in individuals of *Antilophia galeata* captured in a fragment of the Cerrado forest. The microfilariae were photographed, and morphometry analysis was performed using the ImageJ software. One individual was infected (14.2%; n = 7) but with a high intensity of infection (42 microfilariae). It is suggested that the microfilariae found belong to the genus *Eufilaria* spp., since all specimens presented the diagnostic characteristics of the taxon (absence of sheath, pointed tail, and length less than 200 µm). This is the first time that microfilariae parasitising *A. galeata* have been recorded. Considering that microfilariae records are rare in Brazilian wild birds, this record may be useful to support further studies and contribute to the understanding of the conservation of the host species.

**Keywords:** avian diseases, brazilian birds, filariasis, morphometry.

## Primeiro registro de microfilárias em *Antilophia galeata* (Aves: Pipridae)

### Resumo

Nematódeos filarídeos são transmitidos por vetores artrópodes. No hospedeiro vertebrado, habitam o sistema cardiovascular, pulmonar e linfático. Embora a maioria das infecções em aves não seja considerada patogênica, pode haver impactos no fitness. Os objetivos do estudo foram verificar a intensidade de infecção e descrever as microfilárias encontradas em *Antilophia galeata*. Sete indivíduos foram capturados em um fragmento florestal de Cerrado, para coleta de sangue e confecção de extensões sanguíneas. As microfilárias foram fotografadas e foi feita a morfometria através do software ImageJ. Um indivíduo estava infectado (14,20%), mas com alta intensidade de infecção (42 microfilárias). As microfilárias encontradas pertencem ao gênero *Eufilaria* spp., pois todos os espécimes apresentaram as características diagnósticas do táxon (ausência de bainha, cauda pontiaguda, e comprimento menor que 200 µm). Pela primeira vez foram registradas microfilárias parasitando *A. galeata*. Considerando que são raros os registros de microfilárias em aves silvestres brasileiras, este registro pode ser útil para subsidiar estudos posteriores e contribuir para o entendimento da conservação da espécie hospedeira.

**Palavras-chave:** Aves brasileiras, doenças aviárias, filariose, morfometria.

### Introduction

Filarids are threadlike nematode helminths that specialise in parasitizing the tissues and cavities of birds other groups of animals (mammals, amphibians, reptiles). They are transmitted in larval form (microfilariae) by Diptera: (Simuliidae, Culicidae, Cerapotonogonidae), or Phthiraptera (Barlett, 2009). Microfilariae migrate from circulating blood and become adults in the cardiovascular, pulmonary, or lymphatic system. After mating, the females release the larvae into the host's bloodstream, where they are ingested by the vector (Barlett, 2009).

In birds, most filarid infections are considered non-pathogenic (Huang, Tsai, Thongchan, Khatri-Chhetri & Wu, 2016). However, in some cases, infections may negatively

impact host fitness, with records of body weight reduction (Atawal, Mgbeahuruike & Hammers 2019), ataxia (Law, Tully & Stewart, 1993), and death (Muñoz-García *et al.*, 2018).

Detection of filarids in wild birds is considered difficult (Barlett, 2009), as finding adult worms usually requires necropsies (Huang *et al.*, 2016). Microfilariae can be found in blood smear scans, which consist of observation under optical microscopy (Silveira, Belo, Rodello, Pinheiro & Braga, 2010), or by molecular methods, such as PCR, which detects the parasite's DNA in the blood of the host bird (Clark, Wells, Dimitrov & Clegg, 2016). However, for the complete description of the microfilariae it is necessary to visualize and measure the morphological structures, which is

only possible with the blood smears technique (Haas, Baruš, Benedikt & Literák, 2011).

Low detection of microfilariae in birds is common, which can be influenced by the periodicity of the parasites. Some species of microfilariae may have their densities increased in peripheral blood at night (Dreyer & Dreyer, 2001). On the other hand, the majority of Passerine birds are diurnal, restricting their captures at daytime (Haas *et al.*, 2011; Sebaio *et al.*, 2012; Brum *et al.*, 2016). Despite the methodological limitations, microfilariae have been found in bird species from all around the world (Atawal *et al.*, 2019; Brum *et al.*, 2016; Huang *et al.*, 2016; Haas *et al.*, 2011; Clark *et al.*, 2016).

The species in this study was the Helmeted Manakin (*Antilophia galeata*, Lichtenstein, 1823), an endemic Cerrado bird that inhabits the riparian forest understory (Sick, 2001). It measures 13.9 to 14.5 cm in length and weighs 18 to 26.5g (Wikiaves, 2019). It is predominantly territorial, frugivorous, and presents sexual dimorphism in adulthood (Silva & Melo, 2011). In addition, it is considered an important biomonitor of environmental quality in the forested areas of Cerrado (Baesse, Tolentino, Morelli & Melo, 2019).

The objective of this study was to analyse the morphometry and describe the microfilariae found in *Antilophia galeata*.

## Material and Methods

The birds were captured with mist nests exposed in trails between 6:30h and 17:30h in July 2014 in a fragment of the Cerrado forest at the Glória Experimental Farm (18°57'03''S; 48°12'22''O) – Federal University of Uberlândia, in the municipality of Uberlândia, MG, Brazil. The individuals were banded with metal bands provided by the Wild Bird Conservation Research Centre (CEMAVE/ICMBio - - Authorization: 3730 – Registry: 359076). Blood samples were collected by puncture of the metatarsal vein using a sterile disposable needle (8 × 0.3 mm) (SISBIO/ICMBio – Authorization: 44901). For the preparation of blood smears (two per individual), the blood was dripped directly onto a sterile microscope slide and was spread with the aid of a second slide. The slides were fixed with absolute methanol and stained in Giemsa solution and phosphate buffer.

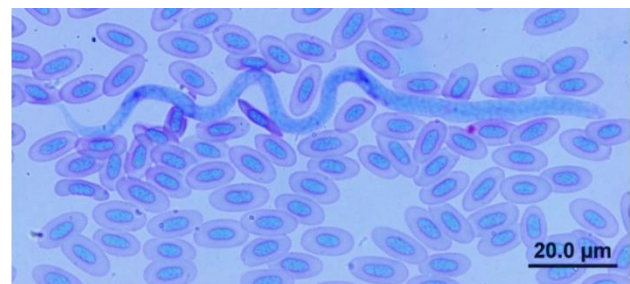
The blood smears were examined under an optical microscope at 100× objective using immersion oil. All detected microfilariae were photographed by a camera (Olympus DP70) attached under a microscope (Olympus BX51). The morphometric measurements of the microfilariae were performed with the aid of the ImageJ 1.x software. The size of the scale bar present in the images was selected and used as a reference value. From this, it was possible to measure the total body length, maximum body width, head space, head width, tail length, tail width, and the distance of the fixed points (nerve ring, excretory pore, inner body, and anal pore) from the anterior end of the microfilariae. Fixed values were expressed as percentages of total body length (Haas *et al.*, 2011).

The intensity of the infection was categorised from the entire slide view according to the criteria of Haas *et al.* (2011), and could be classified into three levels: low (1–10 microfilariae per slide), medium (11–20 microfilariae per slide), and high (>20 microfilariae per slide).

## Results and Discussion

Only one individual (14.2%; n = 7) was infected with microfilariae. It was an adult female (identification: E65838 – CEMAVE/ICMBio) with 16.5 g, without incubation patch, moulting, and ectoparasites. Forty-two microfilariae were counted, with an average of 21 microfilariae per slide, as 22 were observed in one slide and 20 in another, characterised by a high infection.

The morphological aspects of the microfilariae were similar, all being relatively elongated, unshathed, usually extended, or wavy (Figure 1). The anterior extremity (head) was rounded and contained a small head space. The maximum width was observed in the anterior quarter of the body, close to the level of the nerve ring, where the location was indicated from a brief disruption in the microfilariae cell system. The excretory pore was recognised as a short, pale lateral opening, as was the anal pore, the second being located near the beginning of the tail. The inner body was visible as an intensely stained homogeneous space, located toward the back. The specimen body gradually tapered to the posterior end, forming a pointed tail, with the cells almost at the tip. The head space and excretory pore were not visualised in four specimens, the nerve ring and inner body in eight, and the anal pore in two. The morphometric measurements are described in Table 1.



**Figure 1.** Microfilariae photomicrograph found in *Antilophia galeata*.

Based on the specimens' morphological characteristics and according to the descriptions of Barlett (2009), it is suggested that the microfilariae found belong to the genus *Eufilaria* spp.

This is the first record of microfilariae in *A. galeata*, with a prevalence of 14.2% and a high intensity of infection. In the literature, there are different records of prevalence and intensity of infection according to the host taxon. Haas *et al.* (2011) found a prevalence of 20%, 8%, and 2%, and with low intensity of infection in *Turdus merula*, *Turdus philomelos*, *Erithacus rubecula*, respectively, and a prevalence of 50% and medium infection intensity in *Poecile montanus*. Silveira *et al.* (2010) reported a prevalence of 64% and a high intensity of infection in Thamnophilidae. These variations could be considered common, as the occurrence of microfilariae in birds depends on several factors, such as species, sex, age and host ethology, locality, and sampling period (Kučera, 1981; Haas *et al.*, 2011; Atawal *et al.*, 2019).

**Table 1.** Mean, standard deviation, minimum values (min) and maximum values (max) in micrometres ( $\mu\text{m}$ ) of the microfilariae morphometric measurements found in *Antilophia galeata*.

Measurements ( $\mu\text{m}$ )	$\bar{X} \pm \text{SD}$	min - max
Total body length	162 $\pm$ 18.9	110 - 199
Maximum body width	4.63 $\pm$ 0.46	3.75 - 5.38
Tail width	3.30 $\pm$ 0.56	2.23 - 4.63
Tail length	28.7 $\pm$ 5.46	20.7 - 42.1
Head width	3.01 $\pm$ 0.42	2.31 - 3.97
Head space	2.97 $\pm$ 1.18	1.17 - 6.41
Nerve ring (%)*	25.0 $\pm$ 3.99	20.2 - 39.1
Excretory pore (%)*	35.8 $\pm$ 4.30	21.7 - 48.0
Inner body (%)*	67.0 $\pm$ 11.5	34.9 - 77.9
Anal pore (%)*	80.7 $\pm$ 4.21	68.3 - 91.6

\* Proportion of distance from anterior end of microfilariae.

The epidemiology of the microfilariae in wild birds of the Cerrado is unknown, as few studies have reported such parasites in wild birds from this biome (Silveira *et al.*, 2010; Fecchio, Lima, Silveira, Braga & Marini, 2011). However, Fecchio *et al.* (2011) explored the hypothesis of greater exposure to vectors in bird species that build open and higher nests. *A. galeata* nests are open and can be located from 1.15 to 5.64 meters (Marçal & Lopes, 2019). Previous studies have registered other species of Brazilian birds that build open nests, infected by microfilariae, such as: *Formicivora grisea* and *Formicivora rufa* (Silva, 1988; Willis & Oniki 1988; Silveira *et al.*, 2010); *Camptostoma obsoletum* (Fecchio *et al.*, 2011); *Thamnophilus pelzelni* (Silva & Carmo, 2015; Sebaio *et al.*, 2012); *Saltator atricollis* (WikiAves, 2020; Brum *et al.*, 2016). In addition, the individual infected in the present study was female, and it is known that the females of *A. galeata* are solely responsible for the incubation (Marçal & Lopes, 2019). Such behaviour can leave them more exposed to the vectors, as they remain immobile in the nests for long periods. Fecchio *et al.* (2011) also found higher prevalence of blood parasites in birds with gregarious social behaviour. However, *A. galeata* is a highly territorial species that lives in pairs (Sick, 2001). Territoriality is associated with increased levels of hormones that can trigger immunosuppression and consequently greater susceptibility to parasitic infections (Edler, Goymann, Schwabl & Friedl, 2011).

Although the pathogenicity of filarids in birds may be mild, the presence of microfilariae can facilitate the simultaneous occurrence of other infections, such as malaria (Clark *et al.*, 2016). In non-adapted populations, malaria can have disastrous consequences, such as mortality and extinctions (Atkinson & La Point, 2009). Thus, knowing and studying the filarids that affect wild birds is important to minimize the chances of co-infections and their consequences, especially in endemic species of conservation interest such as *A. galeata*.

Benedikt *et al.* (2009) and Haas *et al.* (2011) also found that in some specimens it was not possible to visualize certain morphological features, such as head space, nerve ring, excretory pore, inner body and anal pore. According to Silveira *et al.* (2010), some characteristics of microfilariae are indistinguishable by light microscopy, which may be

associated with the technique of preparing blood smears. Therefore, microfilarial morphology key characteristics are better observed in wet mounts than in dry blood smears (Bartlett, 2009).

The identification of filarid taxa from the visualisation of blood smears is considered complex due to the high degree of morphological and morphometric similarities between these parasites (Mckeand, 1998). However, the morphology of microfilariae could provide useful clues about the identity of the genus (Bartlett, 2009). It is suggested that the microfilariae found in the present study are of the genus *Eufilaria* spp. because all the specimens had the key characteristics of this taxon; the absence of sheath, pointed tail, and length less than 200  $\mu\text{m}$  (Barlett, 2009). In a study of *Poecile montanus* in Central Europe, Haas *et al.* (2011) also grouped the microfilariae in *Eufilaria* spp. due to the shape of the tail. Regarding the species identification of the present study, it was not possible, because adult specimens are needed.

## Conclusion

For the first time, were recorded microfilaria parasitising *A. galeata* and with high intensity of infection. The morphometric analysis allowed the microfilariae genus identification (*Eufilaria* spp.). Biological and behavioural factors of the species, such as sex and type of nest, may possibly have contributed to the emergence of microfilariae. Considering that the records of microfilariae in Brazilian wild birds are rare, this work may be useful to support further studies and contribute to the understanding of the conservation of *A. galeata* and other host species.

## Acknowledgments

We are grateful to the members of the Laboratório de Ornitologia e Bioacústica from Universidade Federal de Uberlândia for their field assistance. This work was supported by the Coordenação de Aperfeiçoamento de Pessoal de Nível Superior - Brazil (CAPES - Finance Code 001), the Fundação de Amparo à Pesquisa do Estado de Minas Gerais - Brazil (FAPEMIG - APQ-01654-12) and the Conselho Nacional de Desenvolvimento Científico e Tecnológico - Brazil (CNPq - PELD - 403733/2012-0).

## References

- Atawal, A. F., Mgbeahuruike, A. C. & Hammers, M. (2019). Microfilarial infections associated with body mass loss of Village Weavers *Ploceus cucullatus*. *Ostrich*, 90(1), 41-44. doi: 10.2989/00306525.2018.1539418
- Atkinson, C. T. & LA Pointe, D. A. (2009). Introduced avian diseases, climate change, and the future of Hawaiian honeycreepers. *Journal of Avian Medicine and Surgery*, 23(1), 53-63. doi: 10.1647/2008-059.1
- Baesse, C. Q., Tolentino, V. C. M., Morelli, S. & Melo, C. (2019). Effect of urbanization on the micronucleus frequency in birds from forest fragments. *Ecotoxicology and Environmental Safety*, 171, 631-637. doi: 10.1016/j.ecoenv.2019.01.026
- Bartlett, C. M. (2009). Filaroid Nematodes. In: C. T Atkinson, N. J. Thomas & D. B. Hunter (Orgs.), *Parasitic Diseases of Wild Birds* (pp. 439-462). Ames: Wiley-Blackwell Publishing.
- Benedikt, V., Barus, V., Capek, M., Havlicek, M. & Literak I. (2009). Blood parasites (*Haemoproteus* and microfilariae) in birds from the Caribbean slope of Costa Rica. *Acta Parasitologica*, 54(3), 197-204. doi:

10.2478/s11686-009-0043-1

- Braga, E. M., Belo, N. O., Pinheiro, R. T., 2010. Técnicas para estudos de hemoparasitos em aves. In: Von Matter, S., Straube, F.C., Accordi, I., Piacentini, V., Candido-Jr, J. F. (Orgs.), *Ornitologia e Conservação: Ciência Aplicada, Técnicas de Pesquisa e Levantamento* (Cap. 17, pp. 395-411). Rio de Janeiro: Technical Books.
- Brum, W.M., Pereira, M.A.V.C., Vita, G.F., Ferreira, I., Mello, E.R., Aurnheimer, R.D. C.M. & Padua, E.D. (2016). Parasitismo em aves silvestres residentes e migratórias da Ilha da Marambaia, Estado do Rio de Janeiro. *Pesquisa Veterinária Brasileira*, 36, 1101-1108. doi: 10.1590/s0100-736x2016001100008
- Clark, N. J., Wells, K., Dimitrov, D. & Clegg S. M. (2016). Co-infections and environmental conditions drive the distributions of blood parasites in wild birds. *Journal of Animal Ecology*, 85(6), 1461-1470. doi: 10.1111/1365-2656.12578
- Dreyer, G. & Dreyer, P. (2001). Diagnóstico Laboratorial da Filariose Bancroftiana. In G. A. De Carli (Org.), *Parasitologia clínica: seleção de métodos e técnicas de laboratório para o diagnóstico das parasitoses humanas* (Cap. 19, pp. 373-394). São Paulo: Editora Atheneu.
- Edler, R., Goymann, W., Schwabl, I. & Friedl, T. W. (2011). Experimentally elevated testosterone levels enhance courtship behaviour and territoriality but depress acquired immune response in red bishops *Euplectes orix*. *Ibis*, 153(1), 46-58. doi: 10.1111/j.1474-919X.2010.01075.x
- Fecchio, A., Lima, M. R., Silveira, P., Braga, É. M. & Marini, M. Â. (2011). High prevalence of blood parasites in social birds from a neotropical savanna in Brazil. *Emu-Austral Ornithology*, 111(2), 132-138. doi: 10.1071/MU10063
- Haas, M., Baruš, V., Benedikt, V. & Literák, I. (2011). Microfilariae in birds in the Czech Republic, including a note on adult nematodes *Eufilaria delicata* in a song thrush *Turdus philomelos*. *Parasitology Research*, 109(3), 645-655. doi: 10.1007/s00436-011-2297-4
- Huang, Y. L., Tsai, S. S., Thongchan, D., Khatri-Chhetri, R. & Wu, H. Y. (2017). Filarial nematode infection in eclectus parrots (*Eclectus roratus*) in Taiwan. *Avian Pathology*, 46(2), 188-194. doi: 10.1080/03079457.2016.1237014
- Kučera, J. (1981). Blood parasites of birds in central Europe. I. Survey of literature. The incidence in domestic birds and general remark to the incidence in wild birds. *Folia Parasitologica*, 28, 13-22.
- Law, J. M., Tully, T. N. Stewart, T.B. (1993). Verminous encephalitis apparently caused by the filarioid nematode *Chandlerella quiscalis* in emus (*Dromaius novaehollandiae*). *Avian Diseases* 37: 597-601.
- Marçal, B. F. & Lopes, L. E. (2019). Breeding biology of the Helmeted Manakin *Antilophia galeata* in an ecotone between the Atlantic Forest and the Cerrado. *Ornithology Research*, 27(1), 1-9. doi: 10.1007/BF03544440
- Mckeand, J. B. (1998). Molecular diagnosis of parasite nematodes. *Parasitology*, 117(7), 86-96. doi: 10.1017/S0031182099004096
- Muñoz-García, C. I., López-Díaz, O., Osorio-Sarabia, D., Martínez-Hernández, F., Villalobos, G., Isaak-Delgado, A. B. & Pleite, C.M.C. (2018). New insights into the clinic histopathological and molecular features of *Pelecitus* (Filarioidea: Onchocercidae) from a raptor bird. *Parasitology research*, 117(10), 3319-3325. doi: 10.1007/s00436-018-6009-1
- Sebaio, F., Braga, É. M., Branquinho, F., Fecchio, A. & Marini, M.Â. (2012). Blood parasites in passerine birds from the Brazilian Atlantic Forest. *Revista Brasileira de Parasitologia Veterinária*, 21(1), 7-15. doi: 10.1590/S1984-29612012000100003
- Silva, C. & Carmo, R. S. (2015). Descrição do ninho, ovo e ninhego da chocado-planalto *Thamnophilus pelzelni* Hellmayr, 1924 (Passeriformes: Thamnophilidae) no Parque Nacional Serra de Itabaina, Sergipe, Brasil. *Atualidades Ornitológicas*, 185, 4-6.
- Silva, J. M. C. (1988). Aspectos da Ecologia e Comportamento de *Formicivora grisea* (Boddaert, 1789) (Aves: Formicariidae) em ambientes amazônicos. *Revista Brasileira de Biologia*, 48, 797-805.
- Sick, H. (2001). *Ornitologia brasileira*. Rio de Janeiro: Editora Nova Fronteira.
- Silva, A. M. & Melo, C. (2011). Frugivory and seed dispersal by the helmeted manakin (*Antilophia galeata*) in forests of Brazilian Cerrado. *Ornitologia Neotropical*, 22, 69-77.
- Silveira, P., Belo, N. O., Rodello, D., Pinheiro, R. T. & Braga, É. M. (2010). Microfilariae infection in wild birds from the Brazilian Cerrado. *Journal of Wildlife Diseases*, 46(4), 1305-1309. doi: 10.7589/0090-3558-46.4.1305
- WikiAves. (2019). Soldadinho (*Antilophia galeata*). WikiAves, a Enciclopédia das Aves do Brasil.
- WikiAves. (2020). Batuqueiro (*Saltator atricollis*). WikiAves, a Enciclopédia das Aves do Brasil.
- Willis, E. O. & Oniki, Y. (1988). Nesting of the Rusty-backed Antwren, *Formicivora rufa* (Wied 1831) (Aves, Formicariidae). *Revista Brasileira de Biologia*, 48, 635-637.

License: Creative Commons CC BY 4.0

This article was published with open access for distribution under the terms of the Creative Commons Attribution License, which allows unrestricted use, distribution, and reproduction in any medium, provided the original work is properly cited.